


PATIENT PRESENTING CLINICAL SIGNS

Tank Divo History: Chronic diarrhea since puppy with no response to diet change or metronidazole. Variable appetite.

SPECIES Physical Examination: Low BCS.

Canine Urinalysis: N/A.

BREED CBC: Pending.

Golden retriever Serum Biochemistry: Pending.

Radiographic Findings: N/A.

SEX

Male

Age

16 months

WEIGHT

75 #

INTERPRETED BY

Remo Lobetti, BVSc,
MMedVet (Med), PhD,
Dipl. ECVIM

ULTRASONOGRAPHIC EXAMINATION OF THE ABDOMEN
Urinary System

Small urinary bladder with a thickened and irregular appearance of the apical wall with the rest of the wall having a normal thickness and appearance. Normal anechoic urine with no sediment or uroliths evident.

Normal trigone area, proximal urethra (0.6 cm), and iliac blood vessels.

Iliac lymphadenomegaly (0.8 x 3.2 cm) with normal shape and echogenic appearance. Ureters not visualized.

Normal renal size (left 7.4 cm, right 7.5 cm), echogenic appearance, cortico-medullary differentiation, pelvis, and capsule.

Reproductive System

Normal size and appearance of the testes (left 3.8 cm, right 4.1 cm) and prostate (2.4 cm).

Adrenal Glands

Normal position, shape, echogenic appearance, and size. Left 0.49/0.35 cm, right 0.53/0.56 cm.

Spleen

Normal size (2.2 cm) with a normal echogenic appearance. Smooth homogenous parenchyma, regular curvilinear capsule, and normal vasculature. No inflammatory, neoplastic, infarction, or infiltrative changes evident.

Liver

Normal size, echogenic appearance, portal markings, and regular curvilinear capsule. No nodules or masses evident.

Gall bladder

Full containing normal anechoic bile. Normal thickness and echogenic appearance of the wall. Normal bile duct (0.3 cm).

IMAGING PERFORMED BY

Sonya Myers, DVM

HOSPITAL NAME

Lake Emma Animal
Hospital

REFERRING VET

Dr Lesmes

INVOICE

304196

DATE

5/6/23


PATIENT
Gastrointestinal

Tank Divo

Thickening of the stomach (0.77 cm), duodenum (0.66 cm), and small intestine (0.53 cm) with no loss of layering or distension of the lumen. Normal thickness and appearance of the ileo-cecal junction and colon (0.28 cm).

SPECIES

Canine

Pancreas

Normal size (left 1.3 cm, right 2.1 cm) with a hypoechogenic appearance and irregular capsule. Subtle hyperechogenic appearance of the mesentery and fat surrounding the pancreas.

BREED

Golden retriever

Free Abdomen
SEX

Mesenteric lymphadenomegaly (1 x 2 cm) with normal shape and echogenic appearance. FNA taken with no obvious post aspirate hemorrhage.

Male

No ascites evident.

Age

16 months

ULTRASONOGRAPHIC FINDINGS

Primary Findings:

- Gastroenteropathy.
- Lymphadenomegaly.
- Pancreatic changes.

WEIGHT

75 #

Secondary Findings:

- Cystitis?

INTERPRETED BY

Remo Lobetti, BVSc,
MMedVet (Med), PhD,
Dipl. ECVIM

INTERPRETATION OF THE FINDINGS & FURTHER RECOMMENDATIONS
IMAGING PERFORMED BY

Sonya Myers, DVM

Etiologies for the gastroenteropathy would be *Helicobacter* gastritis, parasitic enteritis, inflammatory bowel disease, dietary hypersensitivity, and secondary to exocrine pancreatic insufficiency.

HOSPITAL NAME

Lake Emma Animal
Hospital

Etiologies for the lymph nodes would be reactive, hyperplasia, and lymphadenitis, with infiltrative neoplasia a highly unlikely differential diagnosis.

REFERRING VET

Dr Lesmes

Although the appearance of the pancreas is suggestive of pancreatitis both the clinical signs and age do not fit.

Etiologies for the urinary bladder would be artifactual as a result of the small urine volume and cystitis.

INVOICE

304196

Further assessment needs to be based on the pending results but could include urine and fecal analyses, urine culture, TLI and cobalamin assay, cPL/PSL, and endoscopy of the upper GI tract with biopsies.

DATE

5/6/23

Specific therapy would be dependent on an etiological diagnosis.



PATIENT

Tank Divo

SPECIES

Canine

BREED

Golden retriever

SEX

Male

Age

16 months

WEIGHT

75 #

INTERPRETED BY

Remo Lobetti, BVSc,
 MMedVet (Med), PhD,
 Dipl. ECVIM

IMAGING PERFORMED BY

Sonya Myers, DVM

HOSPITAL NAME

Lake Emma Animal
 Hospital

REFERRING VET

Dr Lesmes

INVOICE

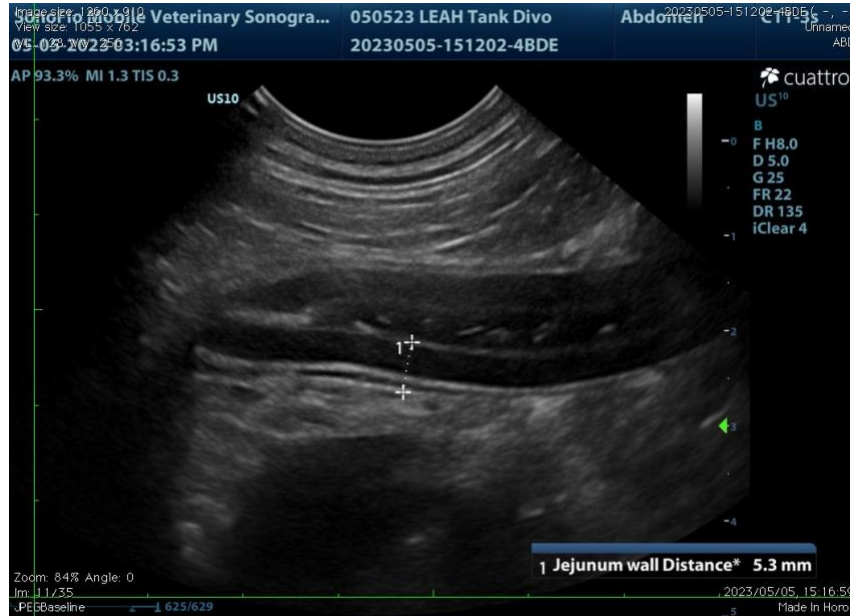304196

DATE

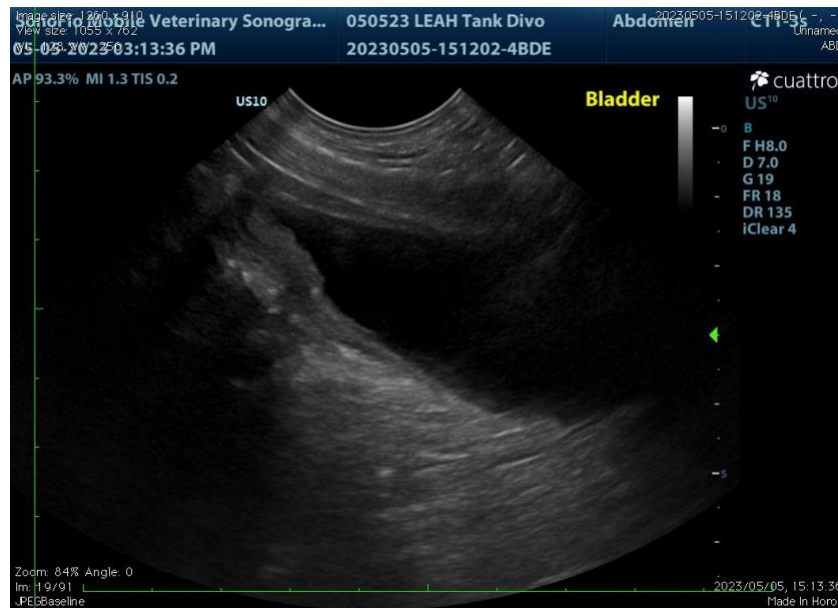5/6/23

IMAGES

Small intestine



Urinary bladder





PATIENT

Lymph nodes

Tank Divo

SPECIES

Canine

BREED

Golden retriever

SEX

Male

Age

16 months

WEIGHT

75 #

INTERPRETED BY

Remo Lobetti, BVSc,
 MMedVet (Med), PhD,
 Dipl. ECVIM

IMAGING PERFORMED BY

Sonya Myers, DVM

HOSPITAL NAME

Lake Emma Animal
 Hospital

REFERRING VET

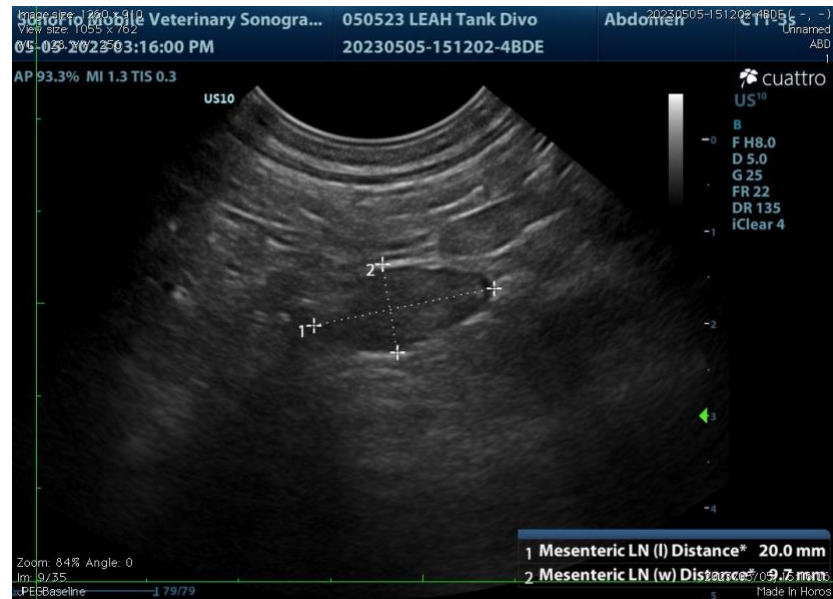
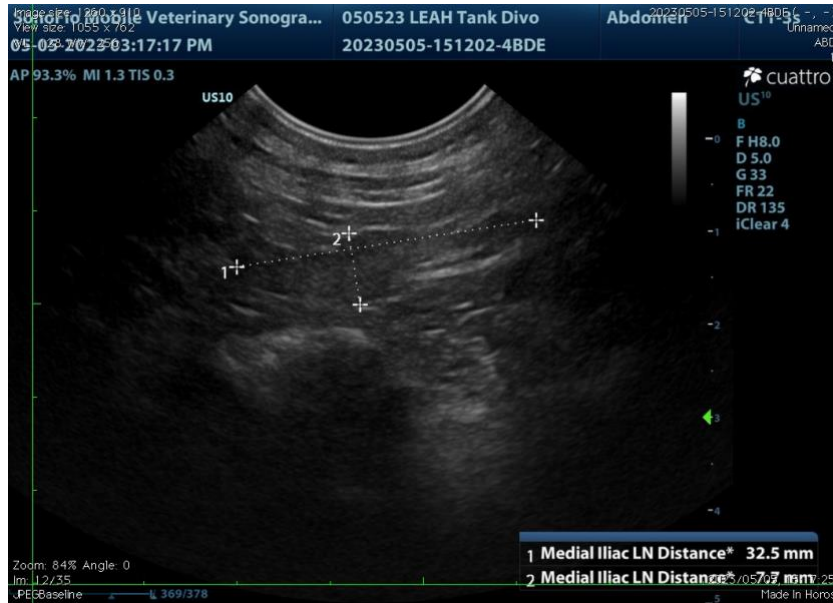
Dr Lesmes

INVOICE

304196

DATE

5/6/23





PATIENT

Pancreas

Tank Divo

SPECIES

Canine

BREED

Golden retriever

SEX

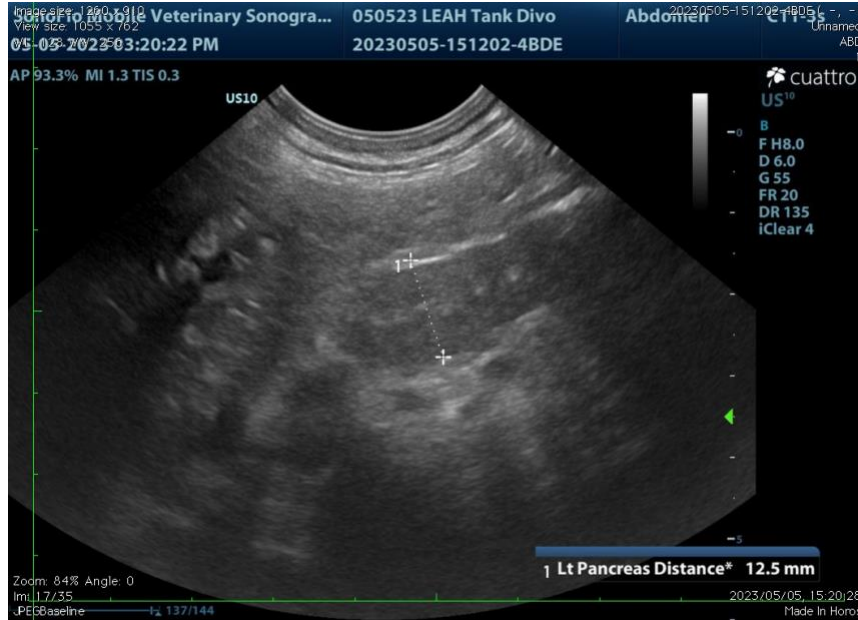Male

Age

16 months

WEIGHT

75 #



INTERPRETED BY

Remo Lobetti, BVSc,
 MMedVet (Med), PhD,
 Dipl. ECVIM

The information and recommendations provided are based on the images presented by the referring veterinarian. No evaluation can be communicated regarding pathology that was not visible in the image/video clips provided.

Thank you for this referral. If the clinical or image interpretation does not parallel your findings or if I can be of any further assistance, please contact me.

Remo Lobetti, BVSc, MMedVet (Med), PhD, Dipl. ECVIM (Internal Medicine)
rlobetti@mweb.co.za

IMAGING PERFORMED BY

Sonya Myers, DVM

HOSPITAL NAME

Lake Emma Animal
 Hospital

REFERRING VET

Dr Lesmes

INVOICE

304196

DATE

5/6/23